

REPRINTED FROM

# ANNALS OF SURGERY

A MONTHLY REVIEW OF SURGICAL SCIENCE AND PRACTICE

EDITED BY

L. S. HILCHER, A.M., M.D.

J. WILLIAM WHITE, M.D.

FREDERICK TREVES, F.R.C.S.

WILLIAM MACLEWEN, M.D.

## TABLE OF CONTENTS

**ORIGINAL MEMOIRS**

1. A Practical Case of Intussusception of the Small Intestine. By Howard A. Kelly. 21

2. The Etiology of the Intussusception of the Small Intestine. By Howard A. Kelly. 21

3. The Etiology of the Intussusception of the Small Intestine. By Howard A. Kelly. 21

4. A Case of Intussusception of the Small Intestine. By Howard A. Kelly. 21

5. A Case of Intussusception of the Small Intestine. By Howard A. Kelly. 21

6. A Case of Intussusception of the Small Intestine. By Howard A. Kelly. 21

7. A Case of Intussusception of the Small Intestine. By Howard A. Kelly. 21

8. A Case of Intussusception of the Small Intestine. By Howard A. Kelly. 21

9. A Case of Intussusception of the Small Intestine. By Howard A. Kelly. 21

10. A Case of Intussusception of the Small Intestine. By Howard A. Kelly. 21

11. A Case of Intussusception of the Small Intestine. By Howard A. Kelly. 21

12. A Case of Intussusception of the Small Intestine. By Howard A. Kelly. 21

13. A Case of Intussusception of the Small Intestine. By Howard A. Kelly. 21

14. A Case of Intussusception of the Small Intestine. By Howard A. Kelly. 21

15. A Case of Intussusception of the Small Intestine. By Howard A. Kelly. 21

16. A Case of Intussusception of the Small Intestine. By Howard A. Kelly. 21

17. A Case of Intussusception of the Small Intestine. By Howard A. Kelly. 21

18. A Case of Intussusception of the Small Intestine. By Howard A. Kelly. 21

19. A Case of Intussusception of the Small Intestine. By Howard A. Kelly. 21

20. A Case of Intussusception of the Small Intestine. By Howard A. Kelly. 21

**TRANSACTIONS OF THE NEW YORK SURGICAL SOCIETY**

Read before the Society at the City Hospital, New York, on the 15th of January, 1898.

1. A Case of Intussusception of the Small Intestine. By Howard A. Kelly. 21

2. A Case of Intussusception of the Small Intestine. By Howard A. Kelly. 21

3. A Case of Intussusception of the Small Intestine. By Howard A. Kelly. 21

4. A Case of Intussusception of the Small Intestine. By Howard A. Kelly. 21

5. A Case of Intussusception of the Small Intestine. By Howard A. Kelly. 21

6. A Case of Intussusception of the Small Intestine. By Howard A. Kelly. 21

7. A Case of Intussusception of the Small Intestine. By Howard A. Kelly. 21

8. A Case of Intussusception of the Small Intestine. By Howard A. Kelly. 21

9. A Case of Intussusception of the Small Intestine. By Howard A. Kelly. 21

10. A Case of Intussusception of the Small Intestine. By Howard A. Kelly. 21

UNIVERSITY OF PENNSYLVANIA PRESS, PHILADELPHIA, PA.

Great Britain: Cassell and Company, London.

\$5.00 a Year in Advance. One Dollar a Year in Advance. Single Copies, Two Shillings.

# KELLY (H.A.)

JANUARY, 1898

## A PRELIMINARY REPORT UPON THE EXAMINATION OF THE BLADDER AND THE CATHETERIZATION OF URETERS IN MEN.

By HOWARD A. KELLY, M.D.,  
Professor of Gynæcology in the Johns Hopkins University.

LIBRARY  
SURGEON GENERAL'S OFFICE  
DEC. 30. 1901  
699.



A PRELIMINARY REPORT UPON THE EXAMINATION OF THE BLADDER AND THE CATHETERIZATION OF URETERS IN MEN.

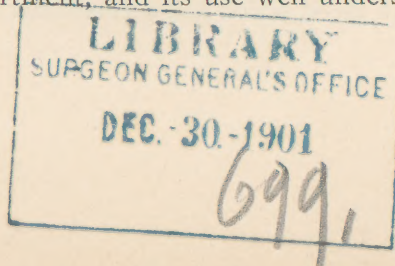
By HOWARD A. KELLY, M.D.,

OF BALTIMORE,

PROFESSOR OF GYNÆCOLOGY IN THE JOHNS HOPKINS UNIVERSITY.

WHEN I first succeeded in my vesical and ureteral examinations in women, in the spring of 1893, I expressed a conviction which I have often restated since then, both to my staff and to visiting physicians at the Johns Hopkins Hospital, that the bladder in the male could also be investigated in a similar manner, and, in all probability, the ureters could be catheterized. So positive was my conviction that I had a long, straight, male cystoscope made by Messrs. F. Arnold & Sons, of this city, November 18, 1893.

Much as I have desired to do so it has been impossible for me to test this instrument until quite recently, owing to the excess of my regular professional obligations always crowding me for time, as well as to the fact that such men as did come under my care were private patients, and although suffering with renal diseases in some instances, I was not at liberty to pursue any line of investigation which might justly be called experimental. I also placed an instrument more than two years ago in the hands of my colleague, Dr. Joseph Bloodgood, of the Johns Hopkins Hospital, who used it to examine the bladder in a case through a perineal section, upon which subject I trust he will have something to say at a future date, but the instrument was not further tested through the intact urethra owing to the fact that the Casper electric cystoscope was already established in the male genito-urinary department, and its use well understood.



I succeeded in securing a patient and testing the method of direct examination in the male bladder, through a simple straight speculum and under atmospheric distention induced by posture, for the first time on November 20 of this year, and I owe this opportunity to the courtesy of the surgical staff of the Johns Hopkins Hospital, and particularly to Drs. Harvey W. Cushing and Hugh H. Young.

The patient, a man about forty-eight years old, had a persistent hæmaturia of undetermined origin. After due antiseptic precautions and washing out the bladder, it was filled with a saline solution and first examined with the Casper cystoscope. For the most part the bladder wall was found normal, but at the base a dark, tufted, villous area was found from which a cloud of blood kept rising and mingling with the clear medium. The conclusion was reached that this was probably a vesical papilloma.

The bladder was then emptied with a catheter and the patient placed in the knee-breast position, with the chest close down to the table, the elbows spread apart, and the thighs slightly drawn up under the abdomen.

The straight cystoscope was then introduced, eight millimetres in diameter, and with a tube eighteen centimetres long, with a funnel-shaped opening and a diminutive handle like those attached to my first cystoscopes used in women. This cystoscope, made for me in November, 1893, was inserted into the bladder by Dr. Young without difficulty, while the patient was still in the dorsal position; when he assumed the knee-breast position the obturator was drawn out and air at once entered the bladder. I attempted to let air into the rectum in order to drop the base of the bladder down more into the plane of vision; but little went in.

The examination of the bladder was now conducted by looking into it through an ordinary head mirror, reflecting an electric light which was held close to the sacrum. The base of the bladder came perfectly into view, and the posterior walls were readily seen. The sound mucosa of the posterior wall showed the characteristic pallor, with small vessels branching here and there over its surface; we were able to see at once that the base was simply coated with blood which had accumulated there in the most de-

pendent position, and that there was no papilloma or other growth present. The trigonum and the interureteric ligament were injected and plainly defined.

I was enabled to see and to demonstrate the orifice of the left ureter and to introduce into it one of the metal catheters which I use in women. While the speculum was held up against the ureter, drops of urine trickled out of it down the tube of the speculum and collected on the edge of the funnel. The urine was claret colored, demonstrating at once the renal source of the hæmaturia. I could not introduce one of my long flexible renal catheters into the ureteral orifice, as I was unable to control the end of the catheter through the long narrow speculum.

The examination was rendered difficult throughout by the insufficient control of the instrument afforded by the small handle; I also found that the tube of the speculum was longer and a little smaller than necessary.

It is a satisfaction to me to be able to show in this report that my expectations have been realized, and I shall hope at a later date to present a fuller account of the methods of examination, with a description of a variety of better instruments for the purpose of examining and exploring the bladder in men. If we can succeed in doing away with the electric cystoscope by substituting a simple, direct method of examination for an expensive, complicated, and even dangerous instrument, the gain will be great.

My direct method of examining also admits of direct methods of treatment. I could, for example, have cut or burned through the pedicle of a papilloma at the base of the bladder with almost the same facility with which I was able to inspect it.





